

# The ultrasound as a significant method in imaging and diagnosing in frequent urgent pediatric incidents, in country region hospitals

## Abstract

The ultrasonography is a significant method in imaging and diagnosing in the most frequent urgent pediatric incidents, in country region hospitals. Our clinical experience of the most frequent in pediatric emergencies of the Emergency Department in our hospital with symptoms of acute abdomen pain. Ultrasound in acute abdomen pain can help in diagnosis of, acute appendicitis, mesenteric lymphadenitis, testicular twisting, twisting epididymis, ovarian twisting, inflammation of the testicles (epididymitis, orchitis), hydronephrosis, inflammation of the urinary tract (pyelonephritis, cystitis, nephritis), hepatosplenomegaly, hypertrophy of pyloric sphincter, bowel intussuseption.

Volume 6 Issue 3 - 2019

Elisavet Glynou, Vasileios Falireas, Eirineos Karamanis, Chalasti Maria, Epistimi Angelou, Athanasios Alexandris, Nikolaos Kapeleris

General Hospital of Kymi "Georgios Papanikolaou," Greece

**Correspondence:** Elisavet Glynou, General Hospital of Kymi "Georgios Papanikolaou," Taxiarchon 9 kymi 34003, Greece, Tel 00302222350132, Email med.e.glynou@gmail.com

**Received:** March 05, 2019 | **Published:** May 27, 2019

## Introduction

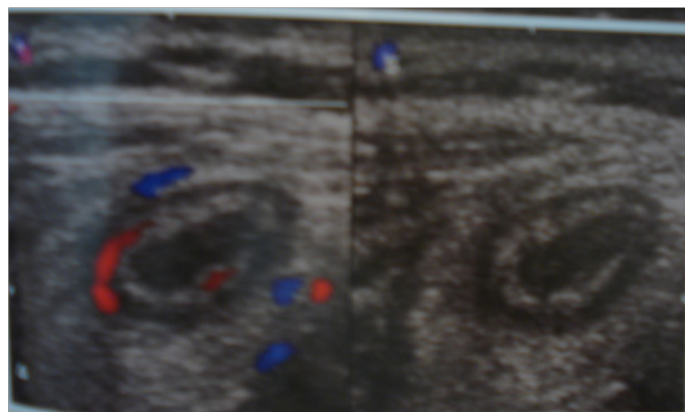
Diagnosis of frequent urgent pediatric incidents in children is clinically challenging specially in country region hospitals. Computed tomography for diagnosis, has a radiation exposure early in life, it's a concern with this technique. Therefore, in this study, we aimed to evaluate the diagnostic reliability of ultrasound in children with acute abdominal pain, to reach a safe diagnosis.

**Purpose:** The ultrasonography is a significant method in imaging and diagnosing in the most frequent urgent pediatric incidents, in country region hospitals.<sup>1-3</sup>

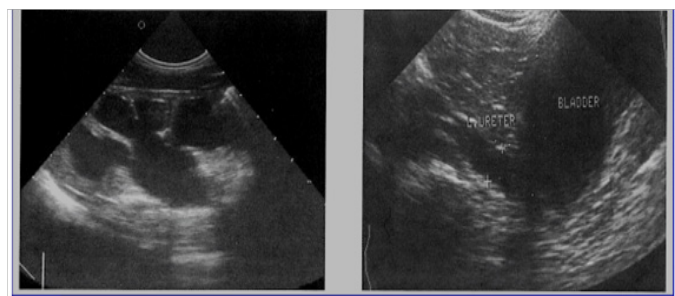
## Materials and method

Our clinical experience of the most frequent in pediatric emergencies of the Emergency Department in our hospital with symptoms of acute abdomen pain. Fifty children examine in our emergency department in the last 2 years with acute abdomen pain. Main age was 10 years old (6 to 14). Thirty-six of them had a pathological ultrasound report (Figures 1-5).

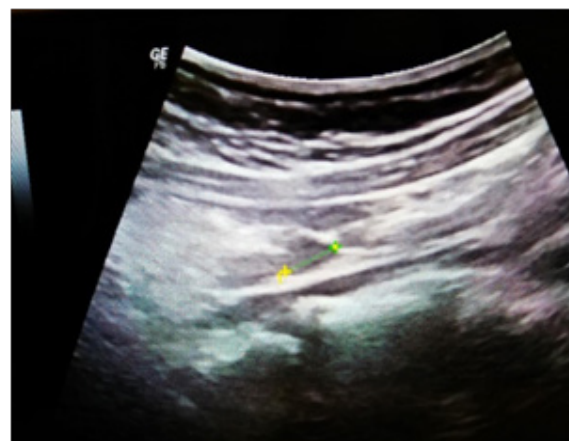Twenty four children were with no significant pathological signs in abdomen ultrasound.



**Figure 1** Eight (5males, 3females) were with acute appendicitis.



**Figure 2** Five (2males, 3females) were with hydronephrosis.

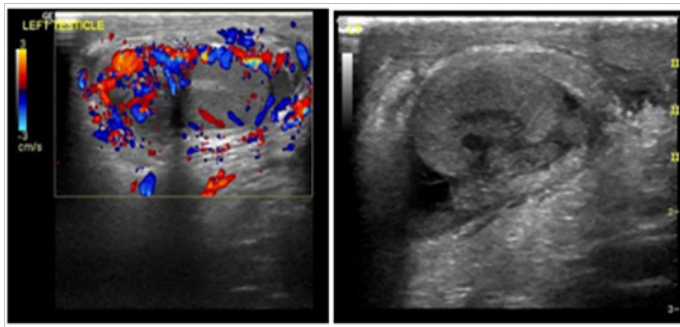


**Figure 3** Eighteen (10males, 8females) were with mesenteric lymphadenitis.

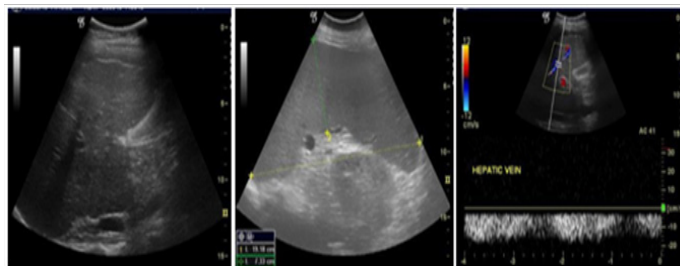
## Results

Ultrasound in acute abdomen pain can help in diagnosis of, acute appendicitis, mesenteric lymphadenitis, testicular twisting, twisting epididymis, ovarian twisting, inflammation of the testicles (epididymitis, orchitis), hydronephrosis, inflammation of the urinary tract (pyelonephritis, cystitis, nephritis), hepatosplenomegaly, hypertrophy of pyloric sphincter, bowel intussuseption.<sup>1,3-8</sup> Ultrasound examination is very important and a low cost examination

with no relevant complications (as CT scan, x rays) that can help in urgent diagnosis in pediatric patients specially in small country hospitals.<sup>1,6,8,9,10</sup>



**Figure 4** One (1male) was with testicular twisting.



**Figure 5** Two (1male, 1female) were with hepatosplenomegaly.

## Discussion

Diagnosis of frequent urgent pediatric incidents in children is clinically challenging. Computed tomography (CT) for diagnosis, has a radiation exposure early in life, it's a concern with this technique. Abdominal US examination showed sensitivity, specificity, and accuracy in diagnosis of, acute appendicitis, mesenteric lymphadenitis, testicular twisting, twisting epididymis, ovarian twisting, inflammation of the testicles (epididymitis, orchitis), hydronephrosis, inflammation of the urinary tract (pyelonephritis, cystitis, nephritis), hepatosplenomegaly, hypertrophy of pyloric sphincter, bowel intussusception. Ultrasound examination is very important and a low cost examination with no relevant complications (as CT scan, x rays) that can help in urgent diagnosis in pediatric patients specially in small country hospitals.

## Acknowledgments

None.

## Conflicts of interest

The authors declare that there is no conflicts of interest.

## References

1. Cartwright SL, Knudson MP. Evaluation of acute abdominal pain in adults. *Am Fam Physician*. 2008;77(7):971–978.
2. Rosen MP, Ding A, Blake MA, et al. ACR Appropriateness Criteria® right lower quadrant pain--suspected appendicitis. *J Am Coll Radiol*. 2011;8(11):749–755.
3. Mandato Y, Reginelli A, Galasso R, et al. Errors in the radiological evaluation of the alimentary tract: part I. *Semin Ultrasound CT MR*. 2012;5(4):300–307.
4. Hoffmann B, Nurnberg D, Westergaard MC. Focus on abdominal air: diagnostic ultrasonography for acute abdomen. *Eur J Emerg Med*. 2012;19(5):284–291.
5. *Standards for providing a 24-hour diagnostic radiology service BFCR(09)3*. London: Royal College of Radiologists;2009.
6. *Practice Standards for Imaging of Children and Young People*. Society College of Radiographers. London: Policy & guidance document library; 2009.
7. Guidelines for Intussusception Reduction. British Society of Paediatric Radiologists. 2003.
8. Aiken JJ, Oldham KT. *Nelson Textbook of Pediatrics*. 20th edn. Philadelphia: Elsevier publisher; 2016:1887–1894.
9. Almaramhy HH. Acute appendicitis in young children less than 5 years: review article. *Ital J Pediatr*. 2017;43(1):15.
10. Seo H, Lee KH, Kim HJ, et al. Diagnosis of acute appendicitis with sliding slab ray-sum interpretation of low-dose unenhanced CT and standard-dose i.v. contrast-enhanced CT scans. *AJR Am J Roentgenol*. 2009;193(1):96–105.